

# Research Report


## Clinically relevant regression of proximal caries

### Authors

Zahnarztpraxis 32schöne Zähne  
Bayreuther Strasse 39, 91301 Forchheim, Germany

Markus Schlee<sup>1</sup>, Florian Rathe<sup>1</sup>, Tatjana Huck<sup>1</sup>, Til Schad<sup>1</sup>, Jan H. Koch<sup>2</sup>, Antje Tjaden<sup>1</sup>, Claudine Bommer<sup>3</sup>

<sup>1</sup>Praxis Dr. Schlee, <sup>2</sup>Dental Text and Consultancy Services, <sup>3</sup>credentis ag



**WILD** REGENAMEL®

# Clinically relevant regression of proximal caries

**Clinical effect of biomimetic mineralization in approximal caries. Interim results of a clinical study after 6 months.**

## Summary

Caries still has a high prevalence even in western countries with preventive dental care. When treated mechanically the long-term often results in tooth loss and substantial inherent costs. In recent years various remineralizing products have been introduced which are supposed to supplement fluorides which in turn promote remineralization. Moreover, specific invasive or minimally invasive options are available, such as proximal sealing and caries infiltration.

## Method

This article presents a new method of biomimetic mineralization based on self-assembling peptides (SAPs).

Suspended in water the SAPs are applied onto the cleaned and etched enamel surface. From there the SAPs will diffuse into the lesion and trigger the formation of a bioactive scaffold, which in turn encourages natural repair through incorporation of calcium and phosphate ions from the saliva.

## Results

According to interim results from a clinical study using biomimetic mineralization, three out of four proximal lesions were stabilized or remineralized. The new method may allow for the first time natural repair of demineralized enamel extending to the enamel-dentin junction.

## Study size

25 patients with a total of 30 treated carious lesions; Follow-up 21 patients with a total of 26 lesions

## Study design

Non-controlled, evaluated by blinded assessors (6 months interim data)

## Main selection criteria

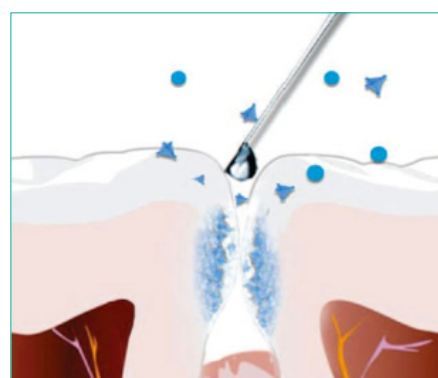
- 1) Proximal caries visible on the clinical x-ray
- 2) Proximal caries not in the need of restorative treatment (E1, E2, very early D1)
- 3) Informed consent

## Diagnostic

Standardised clinical radiographs

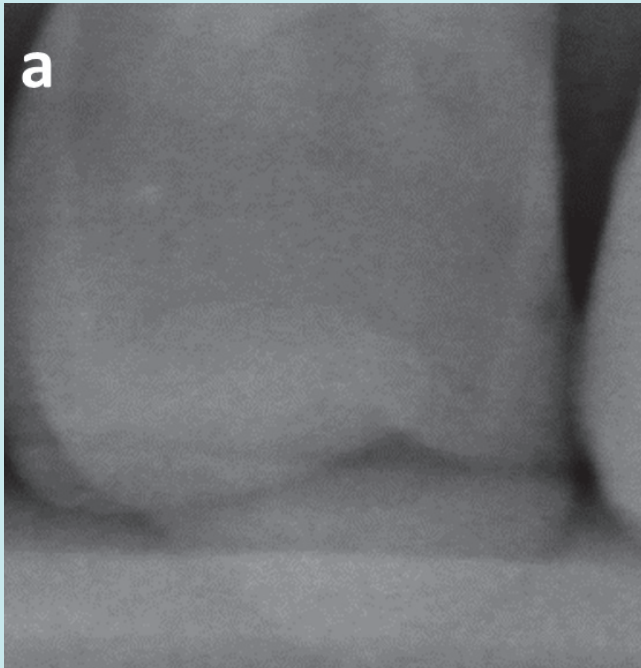
## Main selection criteria

- 1) Professional dental hygiene treatment
- 2) Pre-conditioning with Finier-strips
- 3) 2% Sodium-Hypochloride (20 s) to remove the pellicle
- 4) Etching Gel (35 % Phosphoric Acid; 20 s) to remove amorphous mineral from the pores to the subsurface lesion
- 5) Neutralising with water (20 s)
- 6) Application of REGENAMEL® (3–5 min)

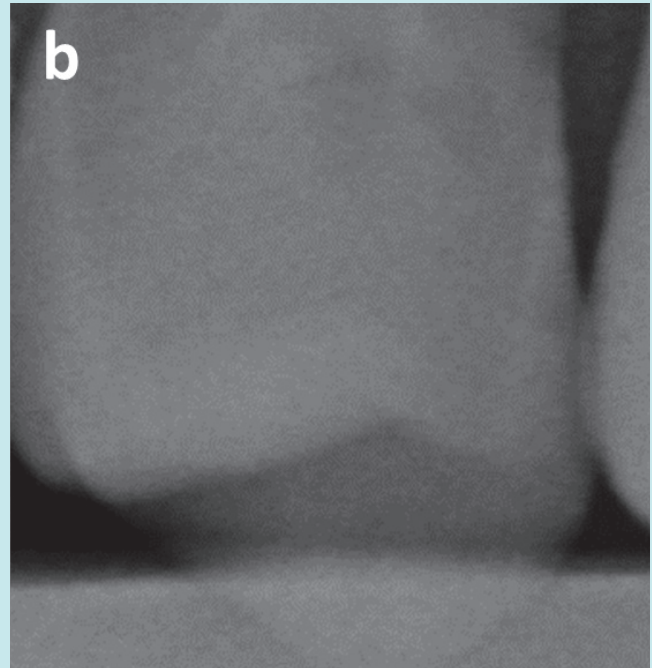


## Follow-up procedure

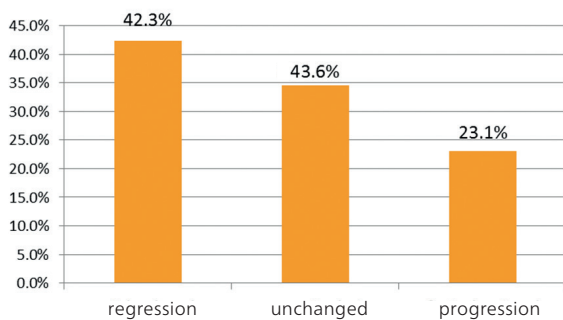
Follow-up after 6 months, 12 months (ongoing)



Standardized radiograph of tooth 26 distal at baseline  $t_0$



Standardized radiograph 26 distal 6 months after REGENAMEL® treatment

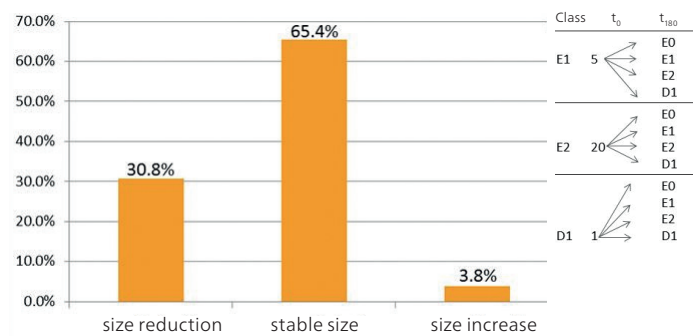


## Results

Assessment of the caries lesions after 6 months with standardized radiographs compared to baseline: 42.3 % regression, meaning visible in-depth mineralisation of the lesion; 43.6 % unchanged size of the lesion, 23.1 % of the lesion showing progression.

## Conclusion

The biomimetic mineralisation offers for the first time the possibility to reform lost enamel crystals underneath the surface. The present study shows that REGENAMEL® – extensively tested in vitro – shows clinically significant improvement.



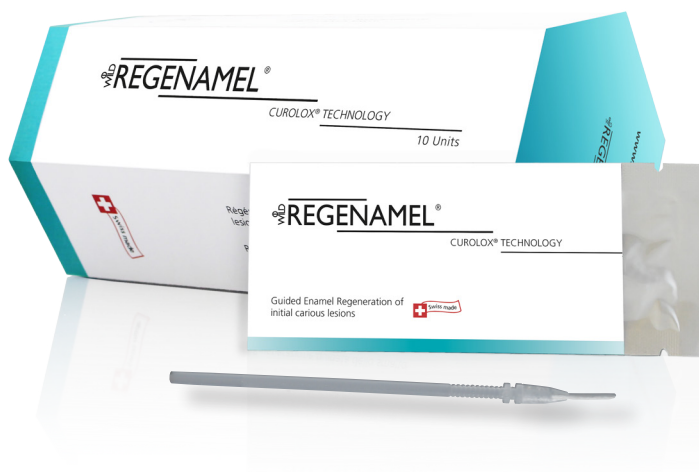Assessment of the lesions after 6 months compared to baseline, regarding the changes within the lesions; 30.8 % showed a reduction in lesion size (e.g E2 -> E1); 65.4 % were stable and 3.8 % (one lesion) showed an increased lesion size.

## Literature

Schlee et al. (2014): Klinischer Effekt biomimetischer Mineralisation bei Approximalkaries Stomatologie 111(4-5); 175-181 DOI 10.1007 / s00715-014-0335-4 [www.credentis.com](http://www.credentis.com)

# WILD REGENAMEL®

Natural filling of initial carious lesions  
and similar defects



For further information,  
please visit our Website:

[www.wild-pharma.com](http://www.wild-pharma.com)



Dr. Wild & Co. AG | Hofackerstrasse 8 | 4132 Muttenz  
[www.wild-pharma.com](http://www.wild-pharma.com) | [info@wild-pharma.com](mailto:info@wild-pharma.com)

 Swiss professional oral care